

Retinal Tears The retina is the inner lining of the eye; it is the thin, light-sensitive tissue that generates vision. Tears can form in the retina, creating a risk of **retinal detachment** and severe loss of vision.

Causes: The vitreous is a clear gel-like substance that fills in the back cavity of the eye which is lined by the retina. At birth, this gel is attached to the retina, but as we age, the gel separates from the retina creating a **posterior vitreous detachment or PVD**. In most cases, this happens without any issue.

However, in people who have an inherently more “sticky” vitreous, as the vitreous separates from the retina, it pulls abnormally (abnormal vitreo-retinal adhesion) and causes the retina to tear. Although retinal tears may also occur as a result of eye trauma, most retinal tears occur spontaneously due to a PVD.

A related entity are retinal holes. The term retinal tears and holes may be used interchangeably by some retina specialists. Retinal tears develop when the vitreous pulls on the retina while retinal holes develop due to progressive thinning of the retina. Retinal holes are typically smaller and have a lower risk for causing a retinal detachment. There are some instances where retinal holes should be treated the same as retinal tears.

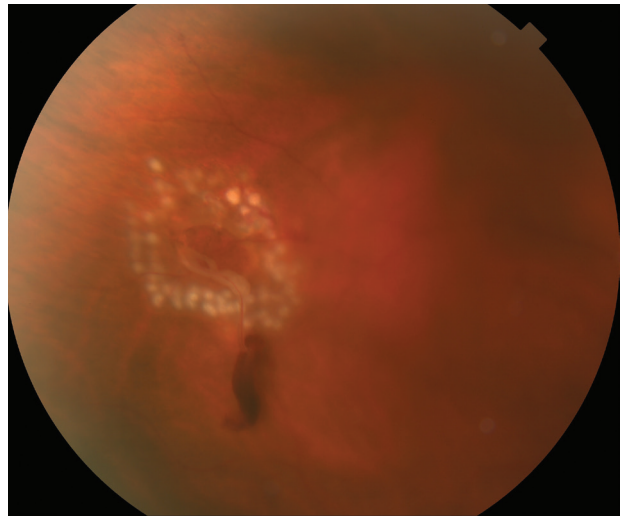


Figure 1

Laser photocoagulation around retinal tear with small hemorrhage. Photo courtesy of Larry Halperin, MD

Risk Factors: Risk factors are not required to develop a retinal tear, but they make the likelihood greater. These factors include:

- Advanced age
- Degree of myopia (nearsightedness)

continued next page

Retinal Tears *continued from previous page*

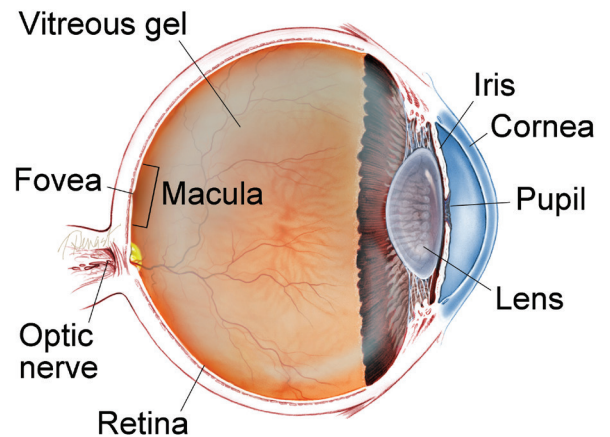
- Associated lattice degeneration (thin patches in the retina)
- Trauma
- Family history of retinal tears or detachment
- Prior eye surgery

There is no way to predict who might develop a retinal tear or when it might occur.

Diagnostic Testing: A thorough and timely examination by a retina specialist using **scleral depression** (applying slight pressure to the eye) and/or a 3-mirror lens is the most important step in diagnosing a retinal tear. In cases where there is a limited view of the retina due to overlying hemorrhage, ophthalmic ultrasound may be required to aid in diagnosing a retinal tear.

Treatment and Prognosis: If a retinal tear is diagnosed promptly before it progresses to retinal detachment, the prognosis is extremely good. Retinal tears are typically treated with laser or a freezing procedure (**cryotherapy**). Treatment is performed in an office setting and is very effective and quite safe.

Topical or local anesthesia is utilized, and the procedure is only mildly uncomfortable. The treatment creates spot-welding around the edges of the tear that nearly eliminates the risk of the tear progressing to retinal detachment. After a tear has been treated, there remains a future risk of developing additional, separate retinal tears; therefore, continued monitoring is important.

WHAT IS THE RETINA?

THE RETINA is a thin layer of light-sensitive nerve tissue that lines the back of the eye (or vitreous) cavity. When light enters the eye, it passes through the iris to the retina where images are focused and converted to electrical impulses that are carried by the optic nerve to the brain resulting in sight.

continued next page

Retinal Tears *continued from previous page*

Not all retinal tears require treatment. When low-risk tears are identified in patients who have no symptoms, these tears can be observed without treatment. Some tears “treat themselves,” meaning they develop adhesion around the tear without treatment, and these situations can be followed without treatment as well. ●

SYMPTOMS

A patient with an acute retinal tear may experience the sudden onset of black spots or “floaters” in the affected eye. This can have the appearance of someone shaking pepper in your vision. Flashes of light (Photopsia) are another common symptom.

If there is associated **vitreous hemorrhage** (bleeding in the clear cavity of the eye) or retinal detachment, additional symptoms can include blurred vision or a shadow as if curtains are closing in from the peripheral (side) vision. However, in some cases, a retinal tear may not manifest any noticeable symptoms. ●

Clinical Terms (appearing green within fact sheet text)

Cryotherapy: A technique in which a pencil-like probe is briefly placed on the white of the eye (sclera). The tip of the probe becomes very cold and can freeze structures inside the eye. This can be used to create a seal around a retinal tear.

Floater: Mobile blurry shadow that partially obscures vision. Floaters are most bothersome when near the center of vision and less annoying when they settle to the side of the vision. They may appear like cobwebs, dust, or a swarm of insects—or in the shape of a circle or oval, called a *Weiss ring*. Floaters are typically more noticeable in bright lighting.

Photopsias (*foe TOP see uhs*): Flashes of light that occur spontaneously within the eye. These are best seen when the surroundings are dark and can appear like lightning flashes, usually in the peripheral vision.

continued next page

Retinal Tears *continued from previous page*

Clinical Terms (*appearing green within fact sheet text*)

Posterior vitreous detachment (PVD): A natural change that occurs during adulthood, when the vitreous gel that fills the eye separates from the retina, which is the light-sensing nerve layer at the back of the eye responsible for sight.

Retinal detachment: A condition where the retina separates from the back of the eye wall. This may be caused by vitreous fluid leaking through a retinal tear or hole and collecting under the retina, causing it to separate from the tissue around it. Think of wallpaper coming unglued and falling off the wall.

Scleral depression: A diagnostic technique where a pencil-like tool is used to gently press on the outside of the eye while the retina specialist looks inside the eye with an indirect ophthalmoscope. The pressure can be mildly uncomfortable, but allows the retina specialist to see portions of the peripheral retina that cannot otherwise be visualized.

Vitreous hemorrhage: A leakage of blood into the gel that fills the eye cavity (also called vitreous humor) that is often the result of blockage or damage to blood vessels in the retina.

THANK YOU TO THE RETINA HEALTH SERIES AUTHORS

Sophie J. Bakri, MD
Audina Berrocal, MD
Antonio Capone, Jr., MD
Netan Choudhry, MD, FRCS-C
Thomas Ciulla, MD, MBA
Pravin U. Dugel, MD
Geoffrey G. Emerson, MD, PhD
K. Bailey Freund, MD
Roger A. Goldberg, MD, MBA
Darin R. Goldman, MD
Dilraj Grewal, MD
Larry Halperin, MD
Vi S. Hau, MD, PhD
Suber S. Huang, MD, MBA
G. Baker Hubbard, MD
Mark S. Humayun, MD, PhD
Talia R. Kaden, MD
Peter K. Kaiser, MD
M. Ali Khan, MD
Anat Loewenstein, MD
Mathew J. MacCumber, MD, PhD
Maya Maloney, MD
Timothy G. Murray, MD, MBA
Hossein Nazari, MD
Oded Ohana, MD, MBA
George Parlitsis, MD
Jonathan L. Prenner, MD
Gilad Rabina, MD
Carl D. Regillo, MD, FACS
Naryan Sabherwal, MD
Sherveen Salek, MD
Andrew P. Schachat, MD
Michael Seider, MD
Janet S. Sunness, MD
Eduardo Uchiyama, MD
Allen Z. Verne, MD
Christina Y. Weng, MD, MBA
Yoshihiro Yonekawa, MD

EDITOR

John T. Thompson, MD

MEDICAL ILLUSTRATOR

Tim Hengst