

Polypoidal Choroidal Vasculopathy

Polypoidal choroidal vasculopathy (PCV) is a disease primarily affecting the vascular layer of blood vessels in the choroid (pronounced CORE oid), resulting in damage to the overlying retina where the photoreceptor cells responsible for vision reside (see illustration).

Causes and Risk Factors: PCV is characterized by abnormally shaped vessels in the **choroid**, but the precise causes of PCV remain a mystery.

We know that PCV:

- Tends to occur in individuals over the age of 60 (but may occur much younger)
- Affects those of Asian and African descent more than Caucasians
- Shares some clinical features with wet age-related macular degeneration

The abnormal vessels in PCV cause vision loss when they leak fluid or blood into or under the retina (Figure 1). The abnormal vessels in PCV may also cause scarring or loss (sometimes called atrophy) of retinal tissue.

Although PCV appears to affect only one eye in some patients, it often goes on to affect both eyes over time, so frequent monitoring is important.

Diagnostic Testing: The most important test used to diagnose PCV is a careful dilated eye examination by your retina specialist. In addition, **fluorescein and indocyanine green (ICG) angiography** may be useful

(Figure 2). These 2 tests are able to create detailed images of the retinal and choroidal blood vessels, which can assist your retina specialist in identifying important abnormalities.

Both tests require a special dye to be injected into a vein (usually in the arm or hand) before retinal photographs are taken. **Optical coherence tomography (OCT)** scanning of the retina is also routinely used to aid in diagnosis of PCV.

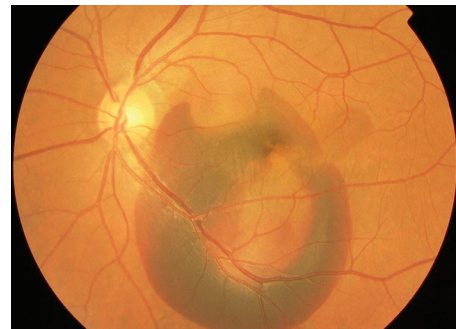
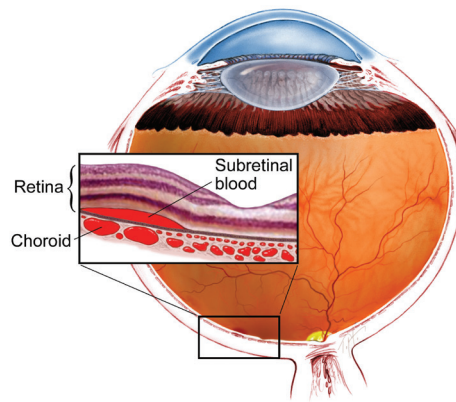


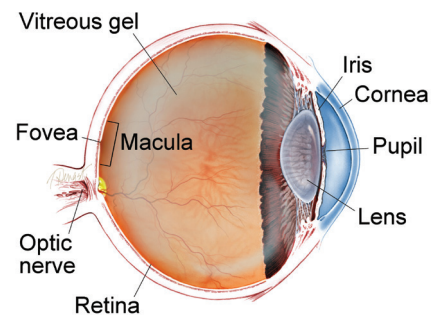
Figure 1
Significant amount of subretinal blood in the macula of a left eye caused by PCV. Image courtesy of the ASRS Retina Image Bank, contributed by Yusuke Oshima, MD, PhD. Osaka University Graduate School of Medicine, 2013. Copyright American Society of Retina Specialists 2016

SYMPTOMS

.....

Patients with PCV often experience blurred vision or a blind spot in (or near) the center of their vision in one or both eyes. These symptoms may appear suddenly and tend not to vary throughout the day. Your retina specialist may even diagnose PCV early before it has caused any symptoms. ●

WHAT IS THE RETINA?



THE RETINA is a thin layer of light-sensitive nerve tissue that lines the back of the eye (or vitreous) cavity. When light enters the eye, it passes through the iris to the retina where images are focused and converted to electrical impulses that are carried by the optic nerve to the brain resulting in sight.

continued next page

Polypoidal Choroidal Vasculopathy *continued from previous page*

Treatment and Prognosis: Unfortunately, some patients with PCV experience irreversible central vision loss in one or both eyes. Early diagnosis and treatment, however, may restore vision and prevent further vision loss in some patients. The most common treatments for PCV are intravitreal (in-the-eye) injections of an anti-VEGF medication and photodynamic therapy (PDT).

Vascular endothelial growth factor (VEGF) is a molecule generated by the body that causes the abnormal vessels in PCV to leak fluid and to bleed into and under the retina. Injections of anti-VEGF drugs into the eye block the activity of VEGF and often result in a decrease in the fluid or blood caused by the abnormal vessels.

Successful treatment of PVC often requires repeat dosing of anti-VEGF medication as frequently as every 4-6 weeks to prevent increased leakage or bleeding. In photodynamic therapy (PDT), an intravenous infusion of a special photosensitizing medication (verteporfin) is injected over 10 minutes; this makes the eye more sensitive to light. Then a cold laser is applied to the retina and choroid to damage or destroy the abnormal blood vessels found in PCV.

On rare occasions, surgical **vitrectomy** (a procedure to remove the eye's vitreous gel) may be used to remove or displace a large hemorrhage caused by PCV. ●

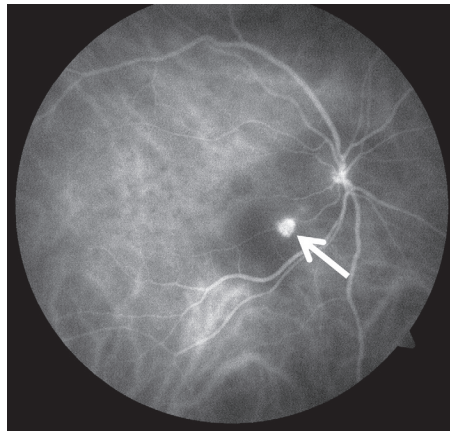


Figure 2
ICG angiography revealing abnormal, balloon-shaped “polyp” in center of right macula (arrow). Image courtesy of the ASRS Retina Image Bank, contributed by John S. King, MD, 2014. Copyright American Society of Retina Specialists 2016

Clinical Terms *(appearing green within fact sheet text)*

Choroid (pronounced CORE oid): The layer of blood vessels and connective tissue between the retina and the white of the eye, also known as the sclera.

Fluorescein angiography (FA): An imaging technique where a yellow dye called sodium fluorescein is injected into a vein in the arm, allowing a special camera to record circulation in the retina and choroid in the back of the eye. This test can be very useful in diagnosing a number of retinal disorders.

Indocyanine green angiography (ICGA): A diagnostic procedure that uses a green dye to illuminate blood flow in the choroid, which is a layer of blood vessels located between the white of the eye (sclera) and the retina that supplies nutrients to the inner eye.

Optical coherence tomography (OCT): A non-invasive imaging technique that uses light to create a 3-dimensional image of your eye for physician evaluation.

Vitrectomy surgery: A procedure undertaken by a specialist where the vitreous gel that fills the eye cavity is removed to provide better access to the retina. This allows for a variety of repairs, including the removal of scar tissue, laser repair of retinal detachments and treatment of macular holes. Once surgery is complete, saline, a gas bubble or silicone oil may be injected into the vitreous cavity to help hold the retina in position while the eye heals.

There are different types of vitrectomy:

- Pars plana vitrectomy is performed by retina specialists to address diseases of the ‘posterior’ (back) segment of the eye cavity, also referred to as the pars plana.
- Anterior vitrectomy is performed by ophthalmologists or retina specialists to address leakage of vitreous gel into the front (anterior) chamber of the eye.

THANK YOU TO THE RETINA HEALTH SERIES AUTHORS

Sophie J. Bakri, MD
Audina Berrocal, MD
Antonio Capone, Jr., MD
Netan Choudhry, MD, FRCS-C
Thomas Ciulla, MD, MBA
Pravin U. Dugel, MD
Geoffrey G. Emerson, MD, PhD
Roger A. Goldberg, MD, MBA
Darin R. Goldman, MD
Dilraj Grewal, MD
Larry Halperin, MD
Vincent S. Hau, MD, PhD
Suber S. Huang, MD, MBA
Mark S. Humayun, MD, PhD
Peter K. Kaiser, MD
M. Ali Khan, MD
Anat Loewenstein, MD
Mathew J. MacCumber, MD, PhD
Maya Maloney, MD
Hossein Nazari, MD
Oded Ohana, MD, MBA
George Parlitsis, MD
Jonathan L. Prenner, MD
Gilad Rabina, MD
Carl D. Regillo, MD, FACS
Andrew P. Schachat, MD
Michael Seider, MD
Eduardo Uchiyama, MD
Allen Z. Verne, MD
Yoshihiro Yonekawa, MD

EDITOR

John T. Thompson, MD

MEDICAL ILLUSTRATOR

Tim Hengst